

The Relationship of Multiple Sclerosis with Brain Lobes and Related Structures: A Volumetric Analysis Study

Multipl Sklerozun Beyin Lobları ve İlgili Yapılarla İlişkisi: Volümetrik Bir Analiz Çalışması

✉ Burak Karip¹, ✉ Özlem Öztürk Köse², ✉ Heval Helin Seykan², ✉ Yunus Emre Akpınar³, ✉ Papatya Keleş¹

¹University of Health Sciences, Hamidiye Faculty of Medicine, Department of Anatomy, İstanbul, Turkey

²Biruni University, Faculty of Medicine, Department of Anatomy, İstanbul, Turkey

³Biruni University, Faculty of Medicine, Department of Radiology, İstanbul, Turkey

Cite this article as: Karip B, Öztürk Köse Ö, Seykan HH, Akpınar YE, Keleş P. The Relationship of Multiple Sclerosis with Brain Lobes and Related Structures: A Volumetric Analysis Study. *J Acad Res Med* 2023;13(2):76-81

ABSTRACT

Objective: Magnetic resonance (MR) imaging techniques are at the center of studies on multiple sclerosis (MS), an autoimmune disorder characterized by demyelination and neurodegeneration in the central nervous system. We aimed to show the differences in the white matter (WM) and cerebrospinal fluid (CSF) volumes in addition to the frontal, temporal, and occipital lobes (OLs) in MS disease and their relations with each other through MR images.

Methods: Images of 50 MS and 50 control group patients randomly selected for use in our study were obtained from Biruni University Faculty of Medicine. Using volBrain software, the volumes of brain structures were calculated on T1-weighted MR images in accordance with the determined parameters. Data analysis was performed using the IBM SPSS 25 package programs.

Results: Volumetric calculations with statistically significant results between groups: abnormal appearance white matter (AaWM) ($p < 0.001$), total volume of WM and gray matter (WMGM) ($p = 0.001$), CSF ($p = 0.002$) and frontal lobe (FL) ($p = 0.024$) volumes. Parameters with high correlation according to correlation analysis; WMGM-CSF ($r = 0.999$), FL supplementary motor cortex (SMC) ($r = 0.742$), FL-temporal lobe (TL) ($r = 0.827$), FL-temporal pole (TP) ($r = 0.652$), SMC-TL ($r = 0.663$), TL-TP ($r = 0.875$), OL-occipital pole ($r = 0.649$) and FL-frontal pole ($r = 0.686$) volumes.

Conclusion: The presence of a decrease in FL and WM against the volumetric increase in AaWM and CSF is the most important of the predicted and significant results in this study. The fact that the significance levels in other parameters are comparatively low indicates that further studies should focus on more specific structures and methods, and all the results obtained can give clinicians a clue for the diagnosis step of MS disease.

Keywords: Multiple sclerosis, MRI, CSF, white matter, brain, T1-weighted

ÖZ

Amaç: Manyetik rezonans (MR) görüntüleme teknikleri, merkezi sinir sisteminde demiyelinizasyon ve nörodejenerasyon ile karakterize otoimmün bir hastalık olan multipl skleroz (MS) ile ilgili çalışmaların merkezinde yer almaktadır. MS hastalığında frontal, temporal ve oksipital lobların (OL) yanı sıra beyaz madde (BM) ve beyin omurilik sıvısı (BOS) hacimlerindeki farklılıkları ve birbirleriyle ilişkilerini MR görüntüleri ile göstermeyi amaçladık.

Yöntemler: Çalışmamızda kullanılmak üzere rastgele seçilen 50 MS ve 50 kontrol grubu hastanın görüntüleri Biruni Üniversitesi Tıp Fakültesi'nden temin edildi. VolBrain yazılımı kullanılarak T1-ağırlıklı MR görüntüleri üzerinde beyin yapılarının hacimleri belirlenen parametrelere göre hesaplandı. Veri analizi IBM SPSS 25 paket programı kullanılarak yapıldı.

Bulgular: Gruplar arasında istatistiksel olarak anlamlı sonuçlara sahip hacimsel hesaplamalar; anormal görünen beyaz madde (AgBM) ($p < 0,001$), beyaz ve gri maddenin toplam hacmi (BMGM) ($p = 0,001$), BOS ($p = 0,002$) ve frontal lob (FL) ($p = 0,024$) hacimleri. Korelasyon analizine göre korelasyonu yüksek olan parametreler; BMGM-BOS ($r = 0,999$), FL suplementer motor korteks (SMK) ($r = 0,742$), FL-temporal lob (TL) ($r = 0,827$), FL-polus temporalis (PT) ($r = 0,652$), SMK-TL ($r = 0,663$), TL-PT ($r = 0,875$), OL-polus occipitalis kutup ($r = 0,649$) ve FL-polus frontalis ($r = 0,686$) hacimleri.

ORCID IDs of the authors: B.K. 0000-0002-6757-4960; Ö.Ö.K. 0000-0001-5107-3726; H.H.S. 0000-0003-3978-8125; Y.E.A. 0000-0001-5216-6289; P.K. 0000-0002-0222-5081.

Corresponding Author/Sorumlu Yazar: Burak Karip,

E-mail: krpbkr@gmail.com



Received Date/Geliş Tarihi: 15.03.2023 **Accepted Date/Kabul Tarihi:** 30.05.2023

©Copyright 2023 by University of Health Sciences Turkey Gaziosmanpaşa Training and Research Hospital.

Journal of Academic Research in Medicine published by Galenos Publishing House.
Licenced by Creative Commons Attribution-NonCommercial-NoDerivatives 4.0 International
(CC BY-NC-ND 4.0) Available on-line at www.jarem.org

Sonuç: AğBM ve BOS'deki hacimsel artışa karşı FL ve BM'de azalma olması çalışmada öngörülen ve anlamlı sonuçların en önemlisidir. Diğer parametrelerdeki anlamlılık düzeylerinin nispeten düşük olması, ileri çalışmaların daha spesifik yapılara ve yöntemlere odaklanması gerektiğini göstermekte ve elde edilen tüm sonuçlar klinisyenlere MS hastalığının tanı basamağı için ipucu verebilir.

Anahtar kelimeler: Multipl skleroz, MRG, BOS, beyaz madde, beyin, T1-ağırlıklı

INTRODUCTION

Multiple sclerosis (MS) is a common and popular disease in society. By definition, the disease begins when a chronic autoimmune deficiency affects the central nervous system. Unlike most important pathologies, its symptoms (inflammation, T cell-mediated demyelination, and axonal loss) appear very early (1,2). Many factors can be effective in the appearance or progression of this disease, the most important of which are environmental, genetic, and epigenetic factors. Although there are more than 2.5 million MS patients worldwide, it is stated that the prevalence of MS in Turkey is between 41.1 and 101.4 per 100,000 people (3). Despite many studies, the large number of factors with which it can interact indicates that there is still a need for new studies on MS (4).

In the clinical reflection of MS, cognitive abnormalities, impairments in attention, and information processing speed can be counted among the major functional disorders. It is known that mental disorders can occur with anatomical damage or lesions in the frontal lobe (FL) of the brain. This situation can be seen as a factor that emphasize the pathology or morphology of the FL of the brain (5). In addition, pathologies in areas where some lesions or changes may compress the optic nerve, such as the retrobulbar region in visually impaired patients, can be seen in the magnetic resonance imaging (MRI) findings of MS patients (6).

Symptoms such as poor memory use and processing of new information in the memory and brain indicate that MS affects the hippocampal region in particular and the temporal lobe (TL) in general (7). One of the most distinctive differential diagnoses of neuromyelitis optica spectrum diseases, which is a type of MS that shows radiologically similar symptoms to MS, is the positive relationship between peripapillary retinal nerve fibers and the gray matter (GM) of the occipital lobe (OL) (8). This may indicate that MS disease may cause the OL (visual cortex) to be affected or that pathology in the relevant region may give a symptom of MS.

Clinical findings and MRI are the two main parameters used by neurologists to diagnose MS. Cerebrospinal fluid (CSF) and evoked potentials are sometimes used to confirm the diagnosis. There is no specific treatment for MS yet, and this varies from patient to patient. Most treatments are aimed at slowing the progression of the disease or stopping it at its current stage. It can also prevent new attacks and the emergence of new symptoms (9).

MS disease should be evaluated from multiple perspectives. The symptoms are seen in the brain, which is the most complex and sensitive area of the human body. When considered holistically,

the brain is examined in 4 main sections; the cerebral cortex, limbic system, basal nuclei, and olfactory system (10). The cerebral cortex is divided into four lobes: FL, parietal lobe, TL, and OL (11,12).

Our study aimed to examine the statistical significance of volumetric measurement calculations of the FL, TL, OL, and related structures of MS patients and healthy individuals, which we think may be closely related to the clinical symptoms of MS and their relationships with each other.

METHODS

Ethics committee approval (decision no: 2023/77-38, date: 06.01.2023) was obtained from Biruni University Non-Interventional Clinical Research Ethics Committee for our study. MRI images were obtained from Biruni University Faculty of Medicine, Department of Radiology. A total of 50 MS and 50 control group patients (25-60 years old) were randomly selected. MR image of a patient in the MS group was not included in the study due to artifacts. The images of 99 patients (35 males, 64 females) including 49 MS (16 males and 33 females) and 50 controls (19 males and 31 females) were subjected to three-dimensional volume measurements in the "volBrain" program (www.volbrain.upv.es).

Parameters included in our study among the outputs obtained from the program (Figure 1) included abnormal appearance of white matter (AaWM), total volume of WM and GM (WMGM), CSF, FL, frontal pole (FP), supplementary motor cortex (SMC), TL, temporal pole (TP), OL and occipital pole (OP). The data obtained

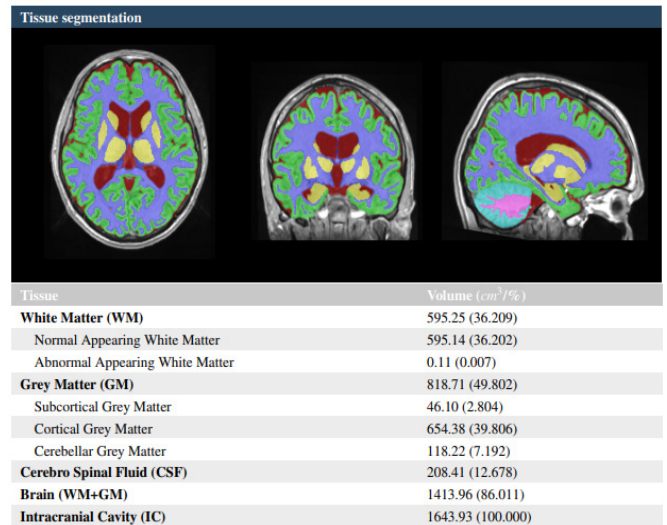


Figure 1. VolBrain PDF report example

for relevant parameters are in the form of percentages. This was a retrospective radiological study. Therefore, the patient consent form was not needed.

Statistical Analysis

Analysis of the data was carried out using IBM SPSS 25 package programs. Qualitative variables frequency and percentage values are presented. The conformity of the data to the normal distribution was tested with the Shapiro-Wilk test. The Mann-Whitney U test was used for comparisons between two-category qualitative and quantitative variables. Chi-square test was used for comparisons between two qualitative variables and Spearman correlation was used for comparisons between two quantitative variables. Type I error rate was taken as 0.05 in the study.

RESULTS

The volumetric measurements of the brain lobes, which is one of the basic parameters of the study, showed that the FL had the highest volume compared to the other lobes studied, while the OL was found to have the smallest volume (Table 1).

Because of the comparisons between MS and control groups; AaWM ($p<0.001$) and CSF ($p=0.002$) values were higher in the MS group; WMGM ($p=0.001$) and FP ($p=0.024$) values were higher in the control group. It was concluded that there was no significant difference between the groups in terms of FL ($p=0.170$), SMC ($p=0.099$), TL ($p=0.113$), TP ($p=0.094$), OL ($p=0.659$) and OP ($p=0.671$) values (Table 2).

Because of examining the existence of a relationship between the percentile values, the relationships between the relevant parameters were determined (Table 3). Parameters with positive and high correlation; FL with SMC ($p<0.001$; $r=0.742$), FL with TL ($p<0.001$; $r=0.827$), FL with TP ($p<0.001$; $r=0.652$), SMC with TL

($p<0.001$; $r=0.663$), TL with TP ($p<0.001$; $r=0.875$), and OL with OP ($p<0.001$; $r=0.649$). Negative and highly correlated parameters; WMGM with CSF ($p<0.001$; $r=0.999$) and FL with FP ($p<0.001$; $r=0.686$).

Parameters with positive and moderate correlation; OL with FL ($p<0.001$; $r=0.497$), SMC with FP ($p<0.001$; $r=0.485$), TL with FP

Table 1. Descriptive statistics

	n (%)
Group	
MS	49 (49.5)
Control	50 (50.5)
Gender	
Male	35 (35.4)
Female	64 (64.6)
Parameters	Median (min-max)
AaWM	0.09 (0-10.82)
WMGM	84.93 (63.45-93.98)
CSF	13.62 (4.38-35.49)
FL	12.11 (5.65-15.05)
FP	0.44 (0.18-0.76)
SMC	0.69 (0.08-0.92)
TL	7.91 (2.4-9.44)
TP	1.29 (0.38-1.85)
OL	5.04 (1.91-6.21)
OP	0.25 (0.1-0.44)

MS: multiple sclerosis, AaWM: abnormal appearing white matter, WMGM: total volume of WM and gray matter, CSF: cerebrospinal fluid, FL: frontal lobe, FP: frontal pole, SMC: supplementary motor cortex, TL: temporal lobe, TP: temporal pole, OL: occipital lobe, OP: occipital pole, min-max: minimum-maximum

Table 2. Comparisons between patient and control groups

Parameters	MS Median (min-max)	Control Median (min-max)	Z	p-value
AaWM	0.15 (0.01-10.82)	0.035 (0-10.81)	-3.725	<0.001*
WMGM	82.2 (63.45-93.98)	86.9 (69.11-93.68)	-3.212	0.001*
CSF	16.42 (4.59-35.49)	11.685 (4.38-29.54)	-3.153	0.002*
FL	11.71 (5.65-14.21)	12.175 (7.04-15.05)	-1.372	0.170
FP	0.43 (0.18-0.6)	0.465 (0.24-0.76)	-2.253	0.024*
SMC	0.67 (0.21-0.82)	0.7 (0.08-0.92)	-1.649	0.099
TL	7.69 (2.4-9.44)	8.14 (2.82-9.2)	-1.585	0.113
TP	1.28 (0.38-1.63)	1.32 (0.53-1.85)	-1.677	0.094
OL	5 (2.07-5.86)	5.105 (1.91-6.21)	-0.441	0.659
OP	0.26 (0.11-0.44)	0.245 (0.1-0.4)	-0.424	0.671
Gender	MS n (%)	Control n (%)	Chi-square	p-value
Male	16 (45.7)	19 (54.3)	0.310	0.578
Female	33 (51.6)	31 (48.4)		

* $p<0.05$, MS: multiple sclerosis, AaWM: abnormal appearing white matter, WMGM: total volume of WM and gray matter, CSF: cerebrospinal fluid, FL: frontal lobe, FP: frontal pole, SMC: supplementary motor cortex, TL: temporal lobe, TP: temporal pole, OL: occipital lobe, OP: occipital pole, min-max: minimum-maximum

($p < 0.001$; $r = 0.542$), TP with SMC ($p < 0.001$; $r = 0.591$), TL with OL ($p < 0.001$; $r = 0.562$), TP with OL ($p < 0.001$; $r = 0.499$), WMGM with FL ($p < 0.001$; $r = -0.458$), WMGM with FP ($p < 0.001$; $r = 0.489$), FL with CSF ($p < 0.001$; $r = -0.453$), and AaWM with CSF ($p < 0.001$; $r = 0.408$). Negative and moderately correlated parameters; AaWM with WMGM ($p < 0.001$; $r = -0.414$), AaWM with FL ($p < 0.001$; $r = -0.524$), AaWM with FP ($p < 0.001$; $r = -0.437$), AaWM with TL ($p < 0.001$; $r = -0.574$), TP with AaWM ($p < 0.001$; $r = -0.571$), OL with AaWM ($p < 0.001$; $r = -0.414$), and FP with CSF ($p < 0.001$; $r = -0.484$).

Parameters with positive and weak correlation; WMGM with SMC ($p < 0.001$; $r = 0.365$), WMGM with TL ($p < 0.001$; $r = 0.399$), WMGM with TP ($p < 0.001$; $r = 0.362$), FP with TP ($p < 0.001$; $r = 0.388$) and OL with SMC ($p < 0.001$; $r = 0.390$). Parameters with negative and weak correlations were AaWM with SMC ($p < 0.001$; $r = -0.359$), AaWM with OP ($p = 0.017$; $r = -0.240$), CSF with SMC ($p < 0.001$; $r = -0.359$), CSF with TL ($p < 0.001$; $r = -0.391$) and TP with CSF ($p < 0.001$; $r = -0.355$).

OL with WMGM ($p = 0.113$), OP with WMGM ($p = 0.121$), OL with CSF ($p = 0.122$), OP with CSF ($p = 0.129$), OP with FL ($p = 0.132$), FP with OL ($p = 0.095$), FP with OP ($p = 0.423$), SMC with OP ($p = 0.203$), TL with OP ($p = 0.077$), and TP with OP ($p = 0.181$) were not significantly correlated.

DISCUSSION

The presence of focal lesions or plaques is one of the most important distinguishing features of MS (13). For many years,

sequences such as double inversion recovery on T2-weighted images have been used to detect disease-related lesions during MS diagnosis, especially in the analysis of WM content (13,14). This method is very important in terms of revealing the abnormal situation in WM. A different condition seen in almost 1 out of every 4 patients in MS pathology is diffusely abnormal WM, which can sometimes be called 'dirty WM' in the clinic (15). T1-weighted images are thought to be associated with more disability progression than T2-weighted images (16). In contrast to the standard, T1-weighted images were used to measure volume independently of the detection of focal lesions or plaques, the goal of our study. One of the parameters we determined on these images is AaWM. Significantly ($p < 0.001$) higher volume of AaWM was detected in MS (0.15) patients compared to the control group (0.035) patients. This finding agrees with the WM abnormality that is mostly seen at the diagnostic stage in MS disease.

Undoubtedly, one of the most important steps in the diagnosis of MS is the analysis of CSF biomarkers. Studies have shown that cerebral blood volume in MS decreases in the later stages of MS prognosis, however, it predicts that there may be an increase in CSF volume (17,18). In our study, CSF volumes were compared between the patient and control groups, and it was observed that the CSF volumes of MS (16.42) patients were significantly higher ($p = 0.002$) than the control group (11.68). In cases where all diagnostic steps cannot be performed, a simple brain MRI image, can be a clue for the early diagnosis of MS.

Table 3. Correlation analysis between percentile values of parameters

		a	b	c	d	e	f	g	h	i
b	r	-0.414**								
	p	<0.001								
c	r	0.408**	-0.999**							
	p	<0.001	<0.001							
d	r	-0.524**	0.458**	-0.453**						
	p	<0.001	<0.001	<0.001						
e	r	-0.437**	0.489**	-0.484**	0.686**					
	p	<0.001	<0.001	<0.001	<0.001					
f	r	-0.359**	0.365**	-0.359**	0.742**	0.485**				
	p	<0.001	<0.001	<0.001	<0.001	<0.001				
g	r	-0.574**	0.399**	-0.391**	0.827**	0.542**	0.663**			
	p	<0.001	<0.001	<0.001	<0.001	<0.001	<0.001			
h	r	-0.571**	0.362**	-0.355**	0.652**	0.388**	0.591**	0.875**		
	p	<0.001	<0.001	<0.001	<0.001	<0.001	<0.001	<0.001		
i	r	-0.414**	0.160	-0.156	0.497**	0.169	0.390**	0.562**	0.449**	
	p	<0.001	0.113	0.122	<0.001	0.095	<0.001	<0.001	<0.001	
j	r	-0.240*	0.157	-0.154	0.152	0.082	0.129	0.178	0.136	0.649**
	p	0.017	0.121	0.129	0.132	0.423	0.203	0.077	0.181	<0.001

* $p < 0.05$, ** $p < 0.01$, a: abnormal appearing white matter, b: total volume of WM and gray matter, c: cerebrospinal fluid, d: frontal lobe, e: frontal pole, f: supplementary motor cortex, g: temporal lobe, h: temporal pole, i: occipital lobe, j: occipital pole

The negative correlation of the total volume of WM and GM in the brain structure with the CSF volume ($p < 0.001$; $r = 0.999$) can be shown as a finding that proves that the CSF volume may increase in parallel with the knowledge of the decrease in the WM volume in MS patients. In addition, the moderate negative correlation between AaWM and WMGM ($p < 0.001$; $r = -0.414$); Since AaWM can be interpreted as causing a decrease in healthy WM volume, a positive moderate relationship between AaWM and CSF ($p < 0.001$; $r = 0.408$) is also parallel to the correlation between WMGM and CSF.

Especially cognitive disorders can occur with anatomical damage or lesions in the FL of the brain. This situation can be seen as a factor that emphasize the pathology or morphology of the FL of the brain. An important example is the damage that may occur in the connections between the FLs and the subcortical structures, which can cause dementia in the relevant region (5,6). Our volumetric measurements show a significant change in MS patients in FL compared with the control group, and a significant change in FP ($p = 0.024$). According to the correlation analysis of SMC, which is also included in FL, in our study groups, although SMC and TL, unlike FL, did not show a significant difference in comparison of study groups, in our study, it was found that SMC was positively and highly correlated with FL ($p < 0.001$; $r = 0.742$) and TL ($p < 0.001$; $r = 0.663$). This may indicate that motor disability, which is frequently evaluated and observed in MS patients, may also be reflected in the volumetric relationships in brain structures (19,20).

Although it is thought that SMC may not have a relationship with OL on a volumetric basis due to the distance between them, it has been reported that changes may occur in the occipital cortex in addition to motor cortex involvement in MS and similar diseases (amyotrophic lateral sclerosis) (21). This may prove the positive and weak relationship between SMC and OL ($p < 0.001$; $r = 0.390$), which emerged because of the correlation analysis in our study.

Because of the statistical analyzes, the parameters that are not significant within themselves, between the groups, and according to the correlation analyzes and their relations with each other are related to the processing of T1-weighted images, which are less frequently used in MR imaging, which is only one of the steps of the diagnosis of MS disease in our study. Based on this, it is not possible to say that parameters that are not significant are not associated with MS disease.

Study Limitations

Even if some MR images had T1-weighted sequences, we could not use some because their section thicknesses were not taken as 1 mm. On the other hand, the images were taken in DICOM format. However, volBrain software can function in NIFTI format which was not applicable to certain images in our study group.

CONCLUSION

In addition to individuals with MS disease, studies with randomly selected images compared with control groups show the

volumetric decrease in the FL, where cognitive disorders occur, and the SMC, which is included in its content, and their positive correlations with each other. As a result of volumetric analysis, it is seen that a decrease in WM and an increase in CSF can occur. It is foreseen that these situations can be an important guide for clinicians.

Our study provides a clue about MS disease, which needs more academic studies from diagnosis to treatment, especially in the early diagnosis stage, that practical programs such as 'volBrain', which are relatively easy to use and provide limited but free access, can be easily used in hospitals with access to MRI.

Ethics Committee Approval: Ethics committee approval (decision no: 2023/77-38, date: 06.01.2023) was obtained from Biruni University Non-Interventional Clinical Research Ethics Committee for our study.

Informed Consent: Retrospective study.

Peer-review: Externally peer-reviewed.

Author Contributions: Surgical and Medical Practices - B.K., Ö.Ö.K., Y.E.A.; Concept - B.K., Ö.Ö.K., H.H.S.; Design - B.K., P.K.; Data Collection and/or Processing - Ö.Ö.K., H.H.S.; Analysis and/or Interpretation - B.K., Y.E.A.; Literature Search - B.K., Ö.Ö.K., H.H.S.; Writing - B.K., Ö.Ö.K., H.H.S., P.K.

Conflict of Interest: The authors have no conflict of interest to declare.

Financial Disclosure: The authors declared that this study has received no financial support.

Etik Komite Onayı: Çalışma için Biruni Üniversitesi Girişimsel Olmayan Klinik Araştırmalar Etik Kurulu'ndan etik kurul onayı (karar no: 2023/77-38, tarih: 06.01.2023) alınmıştır.

Hasta Onamı: Retrospektif çalışmada.

Hakem Değerlendirmesi: Editörler kurulu dışında olan kişiler tarafından değerlendirilmiştir.

Yazar Katkıları: Cerrahi ve Medikal Uygulama - B.K., Ö.Ö.K., Y.E.A.; Konsept - B.K., Ö.Ö.K., H.H.S.; Dizayn - B.K., P.K.; Veri Toplama veya İşleme - Ö.Ö.K., H.H.S.; Analiz veya Yorumlama - B.K., Y.E.A.; Literatür Arama - B.K., Ö.Ö.K., H.H.S.; Yazan - B.K., Ö.Ö.K., H.H.S., P.K.

Çıkar Çatışması: Yazarlar tarafından çıkar çatışması bildirilmemiştir.

Finansal Destek: Yazarlar tarafından finansal destek almadıkları bildirilmiştir.

REFERENCES

- Vidal-Jordana A, Montalban X. Multiple Sclerosis: Epidemiologic, Clinical, and Therapeutic Aspects. *Neuroimaging Clin N Am* 2017; 27: 195-204.
- Choi IY, Piccio L, Childress P, Bollman B, Ghosh A, Brandhorst S, et al. A Diet Mimicking Fasting Promotes Regeneration and Reduces Autoimmunity and Multiple Sclerosis Symptoms. *Cell Rep* 2016; 15: 2136-46.
- Akdemir N, Terzi M, Arslan N, Onar M. Prevalence of Multiple Sclerosis in the Middle Black Sea Region of Turkey and Demographic Characteristics of Patients. *Noro Psikiyatrs Ars* 2017; 54: 11-4.
- Thompson AJ, Baranzini SE, Geurts J, Hemmer B, Ciccarelli O. Multiple sclerosis. *Lancet* 2018; 391: 1622-36.
- Beatty WW. Memory and "frontal lobe" dysfunction in multiple sclerosis. *J Neurol Sci* 1993; 115 Suppl: S38-41.
- Dhanapalaratnam R, Markoulli M, Krishnan AV. Disorders of vision in multiple sclerosis. *Clin Exp Optom* 2022; 105: 3-12.
- Llufriu S, Rocca MA, Pagani E, Riccitelli GC, Solana E, Colombo B, et al. Hippocampal-related memory network in multiple sclerosis: A structural connectivity analysis. *Mult Scler* 2019; 25: 801-10.

8. Manogaran P, Hanson JV, Olbert ED, Egger C, Wicki C, Gerth-Kahlert C, et al. Optical Coherence Tomography and Magnetic Resonance Imaging in Multiple Sclerosis and Neuromyelitis Optica Spectrum Disorder. *Int J Mol Sci* 2016; 17: 1894.
9. Faisal M, Ahmed M, Ahmed A, Bunyan RF. Multiple sclerosis prediction and assessment approaches: a comparison framework. In: 2017 9th IEEE-GCC Conference and Exhibition, GCCCE 2017; Institute of Electrical and Electronics Engineers Inc: 2018. p. 1-9. doi: 10.1109/IEEEGCC.2017.8448109
10. Standring S. *Gray's Anatomy- The Anatomical Basis of Clinical Practice*. 41th ed. Standring S, editor: Elsevier; 2015.
11. Hansen JT. *Netter's Clinical Anatomy, Third Edition*. 3 ed: Elsevier Health Sciences; 2014.
12. Ozan H, editor. *Ozan Anatomi*. 3rd ed. Ankara: Klinisyen Tıp Kitabevleri; 2014.
13. Cairns J, Vavasour IM, Traboulsee A, Carruthers R, Kolind SH, Li DKB, et al. Diffusely abnormal white matter in multiple sclerosis. *J Neuroimaging* 2022; 32: 5-16.
14. Crescenzo F, Marastoni D, Pisani AI, Tamanti A, Dapor C, Colombi A, et al. The Prognostic Value of White-Matter Selective Double Inversion Recovery MRI Sequence in Multiple Sclerosis: An Exploratory Study. *Diagnostics (Basel)* 2021; 11: 686.
15. Ge Y, Grossman RI, Babb JS, He J, Mannon LJ. Dirty-appearing white matter in multiple sclerosis: volumetric MR imaging and magnetization transfer ratio histogram analysis. *AJNR Am J Neuroradiol* 2003; 24: 1935-40.
16. Gajofatto A, Calabrese M, Benedetti MD, Monaco S. Clinical, MRI, and CSF markers of disability progression in multiple sclerosis. *Dis Markers* 2013; 35: 687-99.
17. Wuerfel J. Multiple sclerosis, blood flow, and CSF circulation. *J Cereb Blood Flow Metab* 2013; 33: 1313.
18. Owler BK, Pena A, Momjian S, Czosnyka Z, Czosnyka M, Harris NG, et al. Changes in cerebral blood flow during cerebrospinal fluid pressure manipulation in patients with normal pressure hydrocephalus: a methodological study. *J Cereb Blood Flow Metab* 2004; 24: 579-87.
19. Reilmann R, Holtbernd F, Bachmann R, Mohammadi S, Ringelstein EB, Deppe M. Grasping multiple sclerosis: do quantitative motor assessments provide a link between structure and function? *J Neurol* 2013; 260: 407-14.
20. Svoboda K, Li N. Neural mechanisms of movement planning: motor cortex and beyond. *Curr Opin Neurobiol* 2018; 49: 33-41.
21. Cengiz B, Fidancı H, Baltacı H, Türksöy E, Kuruoğlu R. Reduced Occipital Cortex Excitability in Amyotrophic Lateral Sclerosis. *J Clin Neurophysiol* 2022; 39: 486-91.