

Agensis of Mastoid Antrum

Mastoid Antrum Agenezisi

Çiğdem Tepe Karaca¹, Çağatay Oysu¹, Şaban Çelebi², Ömer Develioğlu², Mehmet Külekçi²

¹Clinic of Otolaryngology Head Neck Surgery, Haydarpaşa Numune Education and Research Hospital, İstanbul, Turkey

²Clinic of Otolaryngology Head Neck Surgery, Taksim Education and Research Hospital, İstanbul, Turkey

ABSTRACT

The significance of the presence of the mastoid antrum is due to its position as an important landmark in the surgical approach to the mastoid. The mastoid antrum is the largest air cell and communicates anteriorly with the attic through an opening called aditus. It is relatively constant bilaterally even in cases of chronic otitis media. Absence of the mastoid antrum may cause severe complications in mastoid surgery. In the English literature, there is only one case of unilateral agenesis of the mastoid antrum in an adult without any congenital abnormality. A healthy 33-year-old male presented to the Department of Otorhinolaryngology with a history of bilateral, intermittently discharging ears. Examination revealed bilateral large central perforations. Pure tone audiometry showed bilateral 28 dB conductive hearing loss across the frequency range. A preoperative computed tomography (CT) scan demonstrated absence of the antrum and a prominent Körner's septum bilaterally. It may be absent only in congenital malformations. In our case, there was no congenital abnormality, but bilateral mastoid antrums were absent. We present the first case of bilateral agenesis of the mastoid antrum without any association with a congenital syndrome. (*JAREM 2012; 2: 24-6*)

Key Words: Mastoid antrum, agenesis, mastoidectomy, ear surgery, Körner's Septum, chronic otitis

ÖZET

Mastoid antrumun varlığının önemi, cerrahi bir landmark olduğu içindir. Mastoid antrum bilateral olarak temporal kemik içinde bulunmaktadır ve en büyük havalı hücredir. Bulunmaması cerrahi sırasında dizoryantasyona sebep olup, fasyal sinir yada labirent yaralanması gibi komplikasyonlara neden olabilir. Kulak cerrahisi yapmak iyi bir anatomi bilgisini gerektirmektedir. Çünkü kulak çok önemli hayati yapılarla komşudur. Mastoid antrumun agenezisinin daha önce yayınlarda bildirilmiş olanlarında hastalarda konjenital anomaliler eşlik ediyordu, bizim hastamızda herhangi bir konjenital anomali yoktu. bu özelliği ile daha önceki vakalardan farklıdır. Biz bu çalışmada polikliniğimize kulak akıntısı ile başvuran sağlıklı 33 yaşındaki bir erkek hastadan bahsediyoruz. Hastanın ameliyat öncesi çekilen bilgisayarlı tomografisinde bilateral mastoid antrumlarının olmadığı tespit edildi. Literatürde konjenital anomalisi olmadan, sadece unilateral mastoid agenezisi olan bir vaka vardır. Bizim hastamızda konjenital anomali olmadan iki taraflı mastoid antrum agenezisi vardır. (*JAREM 2012; 2: 24-6*)

Anahtar Sözcükler: Mastoid antrum, agenezi, mastoidektomi, kulak estetiği, Körner Septum, kronik otitis

INTRODUCTION

The mastoid antrum is an air filled sinus within the petrous part of the temporal bone. It is relatively constant bilaterally even in cases of chronic otitis media. Abnormalities related to the antrum such as the absence of antrum and presence of Körner's septum are anatomical handicaps in mastoid surgery. Failure to recognize its absence can result in disorientation during mastoid surgery, with potential injury to the lateral semicircular canal and/or the facial nerve. Its recognition in the surgical treatment of middle ear and mastoid disease prevents postoperative complications.

CASE REPORT

A healthy 33-year-old male presented to the Department of Otorhinolaryngology with a history of bilateral, intermittently discharging ears. Examination revealed bilateral large central perforations. Pure tone audiometry showed bilateral 28 dB conductive hearing loss across the frequency range. A preoperative computed tomography (CT) scan demonstrated an absent antrum and prominent Körner's septum bilaterally (Figure 1, 2). Because the ears had been dry for more than 1 year, tympanoplasty was not combined with mastoidectomy. The right tympanic membrane

perforation was repaired with temporalis fascia. Three months later the tympanic membrane remains intact and healthy.

DISCUSSION

The adult antrum is an air filled cavity which communicates with the middle ear by way of the aditus and has mastoid air cells arising from its walls. The antrum, but not the air cells, is well developed at birth and, by adult life, has a volume of about 1 ml, being 14 mm from front to back, 9 mm from top to bottom and 7 mm from side to side. The lateral wall is part of the squamous portion of the temporal bone and increases in thickness during life from about 2 mm at birth to 12-15 mm in the adult (1). In the human embryo, the temporal squama begins to ossify first at about eight weeks, petrosa in sixteen weeks. At about 24 weeks gestation, a thin plate of bone from the petrosa grows laterally over the roof of the middle ear cleft to meet a corresponding one from the squama (2). The embryologic petrosquamal suture is where the two lamina of bone meet. So, during development, the antrum is derived from two portions: a deeper petrous portion and a more superficial squamous portion. This early division may leave no trace in the adult and the pneumatic cells may seem to be rather evenly distributed by connecting cell tracts leading to all parts



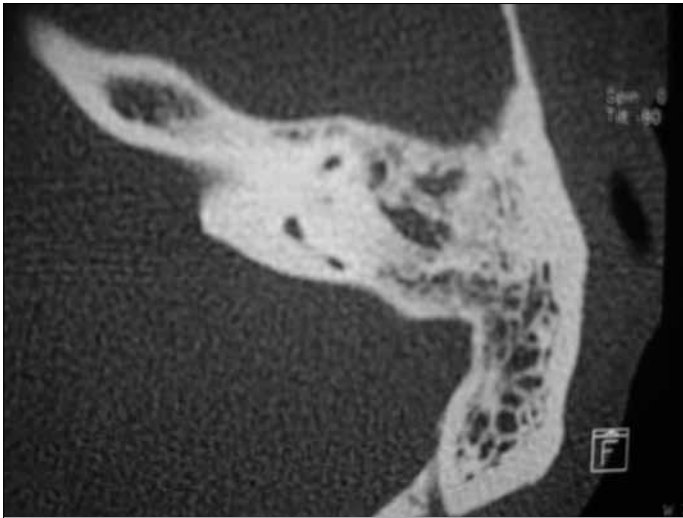


Figure 1. Axial CT scan of right temporal bone

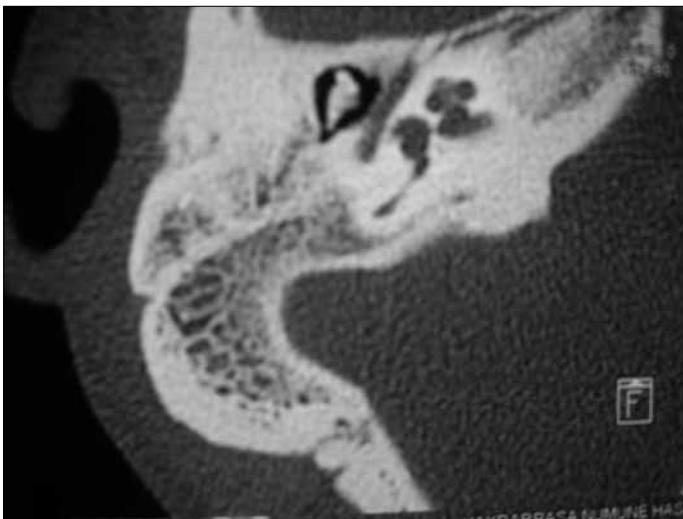

Figure 2. Axial CT scan of left temporal bone

of the mastoid process. The developmental process has been shown to be bilateral and symmetrical.

In the literature, the mastoid antrum is almost always present. It may be higher or lower than the surgical landmark in the region of the posterior root of the zygoma. It may be absent only in congenital malformations. However, in our case, there is no congenital abnormality, but a bilateral absence of mastoid antrum.

The mastoid antrum is the largest air cell and communicates anteriorly with the attic through an opening called the aditus. Posteriorly, the antrum is related to the sigmoid sinus. The roof is separated from the temporal lobe of the brain by the floor of the middle cranial fossa, and the floor is related to the digastric muscle laterally and the sigmoid sinus medially. The medial wall is related to the posterior semicircular canal above. The lateral wall corresponds to Macewen's triangle, which is a standard surgical landmark for identifying the antrum. Its borders are the external canal itself, inferior temporal line, and spine of Henle.

The antrum lies just above and behind the posterosuperior osseous meatal wall a few millimeters lateral to the annulus and sulcus tympanicus. An embryological remnant of the petrosquamos lamina called Körner's septum, can produce the misleading 'false antrum' between those cells that grow downwards into the petrous bone to form the cells of the mastoid process (3, 4). The presented case had bilateral Körner's septae and no antral cavity. In such cases, drilling through Macewen's triangle can cause possible injuries to those neighbouring structures described above.

In a histologic study of the temporal bones of newborns, the mastoid antrum was noted to be present in all subjects, without significant differences for age, gender, or laterality (5, 6). They also revealed that the growth and pneumatization of the temporal bone remained symmetric during the first months of life. Shah et al. (5) reported asymmetric development of the mastoid antrum in a neonate. Physical examination of the infant revealed multiple anomalies. We know that agenesis of the mastoid antrum can occur as part of a group of congenital otological abnormalities in two syndromes; trisomy 13 and mandibulofacial dysostosis. A study of 14 temporal bones of infants with trisomy 13 reported the absence of the mastoid antrum among other abnormalities of the middle ear and inner ear. The characteristic otologic manifestations of the mandibulofacial dysostosis were reported in a study by Hutchinson et al. (7) as a mild symmetric deformity of the auricle, agenesis or hypoplasia of the mastoid and mastoid antrum, absence of the external auditory canal, ossicle abnormalities, tegmen more inferior position than normal, facial nerve pursues an abnormal course, a normal inner ear, normal bone conduction with a marked conductive hearing loss.

Our case is the first to be reported having bilateral agenesis of the mastoid antrum. Because the mastoid antrum, but not the air cells, are well developed at birth, absent bilateral antrum in the reported case could be regarded as a congenital formation not an acquired one.

This case reveals the importance of radiologic imaging of the temporal bone, because mastoidectomy without CT may result in serious complications in such cases as ours. So, radiologic imaging of the temporal bone is very important in patients with chronic otitis media, even in ear surgeries without mastoidectomy.

CONCLUSION

Bilateral agenesis of the mastoid antrum with bilateral Körner's septae in an adult without any congenital abnormality has never been reported before. The surgeon must be aware of their existence otherwise disorientation may cause undesirable injuries to vital structures.

Conflict of interest: No conflict of interest was declared by the authors.

REFERENCES

1. Wright Anthony (1997) Scott-Brown's Otolaryngology 6th edn. Oxford: Butterworth-Heinemann International Editions.
2. Virapongse C, Sarwar M, Bhimani S, Sasaki C, Shapiro R. Computed tomography of temporal bone pneumatization: 1. Normal pattern and morphology. AJR Am J Roentgenol 1985; 145: 473-81.

3. Saleh HA, Murty GE, O'Donoghue GM. Isolated agenesis of the mastoid antrum. *J Laryngol Otol* 1994; 108: 497-9. **[CrossRef]**
4. Shah RK, Vasanth A, Karmody CS. Asymmetric agenesis of the mastoid antrum in a neonate. *Ear Nose Throat J* 2009; 88: 729-30.
5. Valtonen H, Karmody C. Development of mastoid antrum. In: recent advances in otitis media; Proceeding of the 6th International Symposium on otitis media. Hamilton, Ontario: BC Decker, Inc; 1996:124-6.
6. Diamant M. Studies on causative factors of mastoid pneumatization. *AMA Arch Otolaryngol* 1958; 68: 587-97. **[CrossRef]**
7. Hutchinson JC Jr, Caldarelli DD, Valvassori GE, Pruzansky S, Parris PJ. The otologic manifestations of mandibulo facial dysostosis. *Trans Sect Otolaryngol Am Acad Ophthalmol Otolaryngol* 1977; 84: ORL520-8.