



Extended Fetal Bradycardia

Uzamış Fetal Bradikardi

Servet Gençdal¹, Kahraman Ülker¹, Murat Bozkurt¹, Melek Çiçek¹, Yetkin Karasu¹, Duygu Kara Bozkurt², Levent Şahin¹, Emre Destegül³, Gülnur Özaksid¹

¹Department of Obstetrics and Gynecology, Kafkas University Faculty of Medicine, Kars, Turkey

²Department of Radiology, Kafkas University Faculty of Medicine, Kars, Turkey

³Clinic of Obstetrics and Gynecology, Kayseri Training and Research Hospital, Kayseri, Turkey

ABSTRACT

The purpose of this case report is to summarize a case of fetal sinus bradycardia resolving spontaneously. In this case report, we summarized a pregnant woman at 22nd gestational week with fetal bradycardia. There was no medical history about fetal bradycardia. Physical examination was normal. Detailed fetal ultrasound examination and fetal echocardiography were also normal. There were no cardiac malformation and fetal hydrops. Fetal bradycardia was diagnosed by M-mode Doppler ultrasound. Heart beat was 78/min. The family was informed about the situation and followed conservatively. After 2 weeks of follow-up, fetal heart rate had returned to its normal pattern. She delivered at 39th gestational week. Postpartum fetal physical and cardiac examinations were normal. The widespread use of fetal echocardiography in the diagnosis of fetal bradycardia among obstetricians would facilitate the determination of the type of fetal bradycardia. (*JAREM 2015; 5: 139-41*)

Keywords: Fetal sinus bradycardia, fetal echocardiography, ultrasonography

ÖZ

Uzamış fetal bradikardi nedenleri arasında tam atriyoventriküler blok, atriyal bigemini ve sinüs bradikardisi yer almaktadır. Fetal sinüs bradikardisine neden olabilecek çeşitli durumlar mevcuttur. Uzun dönem prognoz, fetal bradikardinin tipine göre değişiklik göstermektedir. Bu çalışmamızda takip neticesinde, spontan olarak gerileyen uzamış fetal sinüs bradikardisi olan olgu sunumu amaçlanmıştır. 22 hafta primigravid gebe kliniğimize fetal bradikardi ön tanısı ile gönderildi. Gebenin anamnez, fizik muayene ve laboratuvar incelemesinde herhangi anormallik saptanmadı. Fetus ultrasonografi, fetal ekokardiyografi ile değerlendirildi ve yapısal kardiyak anomali izlenmedi, fetal hidrops yoktu. M-mod ve Doppler ultrasonografi neticesinde fetal sinüs bradikardisi (78/dk) tanısı konuldu ve gebe izleme alındı. Takibin ikinci haftasında fetal kardiyak ritim normale döndü. Gebelik takiplerinde sorun yaşanmayan gebe normal vajinal yolla doğurtuldu, yenidoğanın pediyatrik kardiyolog tarafından yapılan muayenesinde herhangi bir anormallik saptanmadı. Halen 3. ayında olan yenidoğanda bradikardi izlenmedi. Fetal bradikardinin tanısında fetal ekokardiyografinin kullanımının obstetrisyenler arasında yaygınlaşması, fetal bradikardinin tipinin tespitinde kolaylık sağlayacaktır. (*JAREM 2015; 5: 139-41*)

Anahtar Kelimeler: Fetal sinüs bradikardisi, fetal ekokardiyografi, ultrasonografi

INTRODUCTION

American College of Obstetrics and Gynecology (ACOG) defines fetal bradycardia as fetal heart beat below 110/min (1). Fetal bradycardia constitutes almost 5% of all fetal arrhythmias (2). Causes of fetal bradycardia are vagal stimulation caused by umbilical cord compression, maternal hypotension, convulsion, and drug use. Because prolonged fetal bradycardia may cause fetal hypoxia and acidosis, the etiology of fetal bradycardia must be investigated carefully to prevent possible fetal morbidity and mortality. In this report, we summarized a case of prolonged fetal bradycardia that resolved spontaneously.

CASE PRESENTATION

A 22-year-old woman at 22nd gestational week pregnancy was referred to our clinic with the diagnosis of fetal bradycardia. Her medical history was uneventful and she was not on a drug therapy. There was no cardiac anomaly or any kind of rhythm problem in her family. Second trimester screening was also normal. Ultrasound examination [GE Voluson Pro V (GE Healthcare, Tiefenbach, Austria) 4–7 MHz abdominal convex transducer] re-

vealed a 21-week-old singleton gestation. Fetal examination was normal but fetal bradycardia was consisted (78/min). There were no cardiac malformations. Fetal bradycardia was verified with M-mode and pulse Doppler ultrasound examinations (Figure 1, 2). On fetal echocardiography, four chamber views were normal; valvular and great vessel diameters were normal. No valvular regurgitation was noted, and venous flows (ductus venosus and inferior vena cava) were normal. The arterial duct as well as the foramen ovale were patent. The ratio of early to late-filling peaks showed no inversion at tricuspid and mitral valvular orifices, and the morphology was found to be normal with sustained bradycardia. Ventricles and atria were found to be synchronous; fetal heart rate was measured from atrial or ventricular M-mode waveforms of five consecutive cardiac cycles, and it was also measured from the aortic or pulmonary valve Doppler waveforms of five consecutive cardiac cycles obtained during fetal quiescence that varied between 78 and 82 beats/minute. All these findings indicated sinus bradycardia, and characteristic patterns of flow reversal are observed in the inferior vena cava in association with the premature beat of blocked atrial bigeminy; abnormal, early

This case report presented in İstanbul 4th Obstetrics Days, 27 February-1 March, İstanbul, Turkey.

Bu olgu sunumu İstanbul 4. Kadın Doğum Günlerinde sunulmuştur, 27 Şubat-1 Mart, İstanbul, Türkiye



Address for Correspondence / Yazışma Adresi: Dr. Murat Bozkurt,
E-mail: jindrmb@yahoo.com

Received Date / Geliş Tarihi: 02.03.2015 Accepted Date / Kabul Tarihi: 18.03.2015

© Copyright 2015 by Gaziosmanpaşa Taksim Training and Research Hospital. Available on-line at www.jarem.org

© Telif Hakkı 2015 Gaziosmanpaşa Taksim Eğitim ve Araştırma Hastanesi. Makale metnine

www.jarem.org web sayfasından ulaşılabilir.

DOI: 10.5152/jarem.2015.693

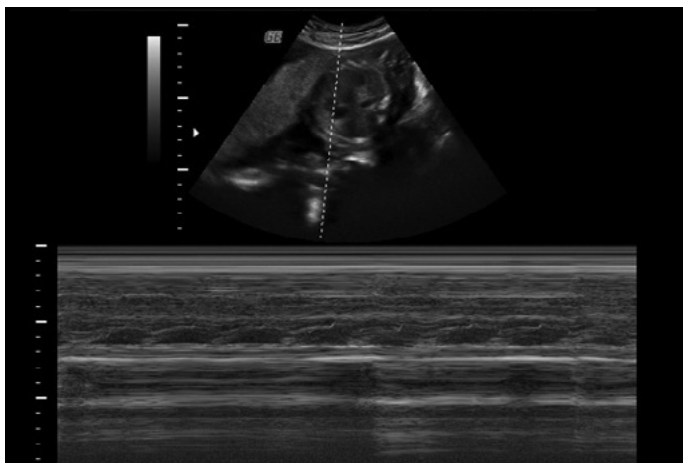


Figure 1. One-to-one ratio with M-Mode method atrioventricular conduction

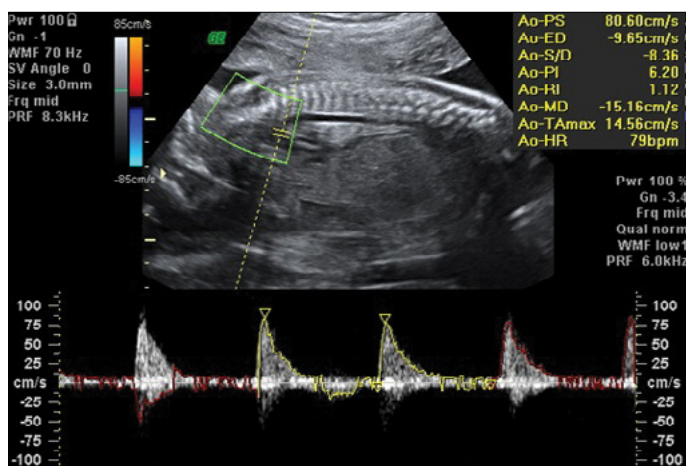


Figure 2. Pulse Doppler cardiac tracings obtained with the arcus aorta

premature contractions may be observed on fetal M-mode. The patient's routine laboratory analysis and electrocardiography were also normal. Anticardiolipin antibody, antinuclear antibody, rheumatoid factor, and anti-Ro and anti-La antibody tests were also normal. The patient was followed conservatively. After one week of follow-up, the fetus still had bradycardia (82/min). Fetal heart rate was normalized at the 24th week of pregnancy (125/min). She delivered at the 39th gestational week with no complications. Postpartum fetal physical and cardiac examinations were normal. The patient gave an informed consent for the publishing of data.

DISCUSSION

Prolonged fetal bradycardia is a rare finding that can be observed during routine fetal ultrasound examination (2). These patients should be evaluated carefully with ultrasound and echocardiography in the aspect of cardiac malformations, fetal hydrops, atrioventricular relationship. Fetal echocardiographic examination is crucial to evaluate fetal arrhythmias. Arrhythmias were diagnosed easily with M-mode Doppler ultrasound examination. Prolonged fetal bradycardia can be classified as follows: complete atrioventricular block (CAVB), sinus bradycardia, and bigeminy premature atrial block (3). CAVB is the most common cause of fetal brady-

cardia. Left atrial isomerism, atrioventricular canal defect or structurally corrected transposition exist in almost 50% of cases (4). CAVB should be excluded because its prognosis is bad. Collagen diseases, such as maternal systemic lupus, may cause either 1st, 2nd, or 3rd degree block or severe fetal bradycardia characterized with enlarged QRS complex (5). Serologic test results were normal in our patient. Our diagnosis was fetal sinus bradycardia because we did not observe any cardiac malformation, and atrioventricular relationship is completely normal. Usually, an etiological factor cannot be found in sinus bradycardia cases. Prolonged fetal bradycardia may develop because of maternal drug use, which can cause fetal stress, acidosis, hypoxia, and long QT and sick sinus syndromes (6). Reported cases in the literature showed that maternal hypothermia and hypoglycemia may also cause fetal bradycardia. In these cases, heart rhythm resolves after the regulation of underlying reason (7). In our case, none of these reasons were observed. Fetal sinus bradycardia does not have a specific treatment and is not correlated with the hemodynamic instability of the fetus (8). This case was managed conservatively by only performing a close follow-up. After two weeks of fetal sinus bradycardia, it resolved spontaneously. If there is no sign of heart failure with coexisting bradycardia, vaginal delivery is the method of choice for terminating the pregnancy (9).

CONCLUSION

In this case, the patient delivered vaginally. In conclusion, the prognosis of prolonged fetal bradycardia depends on the underlying pathology. The widespread use of fetal echocardiography in the diagnosis of fetal bradycardia among obstetricians would facilitate the determination of the type of fetal bradycardia.

Informed Consent: Written informed consent was obtained from patient who participated in this case.

Peer-review: Externally peer-reviewed.

Author Contributions: Concept - M.B., S.G., K.Ü., M.Ç., Y.K., O.K.B., L.Ş., E.D., G.Ö.; Design - M.B., S.G., K.Ü., M.Ç., Y.K., O.K.B., E.D., G.Ö.; Supervision - M.B., S.G., K.Ü., M.Ç., Y.K., O.K.B., L.Ş., E.D., G.Ö.; Data Collection and/or Processing - M.B., S.G.; Analysis and/or Interpretation - M.B., S.G.; Literature Search - M.B., S.G.; Writing Manuscript - S.G., M.B.; Critical Review - M.B., S.G.

Conflict of Interest: No conflict of interest was declared by the authors.

Financial Disclosure: The authors declared that this study has received no financial support.

Hasta Onamı: Yazılı hasta onamı bu olguya katılan hastadan alınmıştır.

Hakem değerlendirmesi: Dış bağımsız.

Yazar Katkıları: Fikir - M.B., S.G., K.Ü., M.Ç., Y.K., O.K.B., L.Ş., E.D., G.Ö.; Tasarım - M.B., S.G., K.Ü., M.Ç., Y.K., O.K.B., E.D., G.Ö.; Denetleme - M.B., S.G., K.Ü., M.Ç., Y.K., O.K.B., L.Ş., E.D., G.Ö.; Veri toplaması ve/veya İşlemesi - M.B., S.G.; Analiz ve/veya Yorum - M.B., S.G.; Literatür Taraması - M.B., S.G.; Yazıyı Yazan - S.G., M.B.; Eleştirel İnceleme - M.B., S.G.

Çıkar Çatışması: Yazarlar çıkar çatışması bildirmemişlerdir.

Finansal Destek: Yazarlar bu çalışma için finansal destek almadıklarını beyan etmişlerdir.

REFERENCES

1. ACOG Practice Bulletin No.106: Intrapartum fetal heart rate monitoring: nomenclature, interpretation, and general management guidelines. *Obstet Gynecol* 2009; 114: 192-202. [\[CrossRef\]](#)
2. Wladimiroff JW, Stewart PA, Tonge HM. Fetal bradyarrhythmia: diagnosis and outcome. *Prenat Diagn* 1988; 8: 53-7.
3. Carvalho JS, Jaeggi E. Sustained fetal bradycardia: Mechanisms and pitfalls. *Ultrasound Obstet Gynecol* 2006; 28: 407. [\[CrossRef\]](#)
4. Buyton JP, Swersky SH, Fox HE, Bierman FZ, Winchester RJ. Intrauterine Therapy for presumptive fetal myocarditis with acquired heart block due to SLE. *Arthritis Rheum* 1987; 30: 44-9. [\[CrossRef\]](#)
5. Kalush F, Rimon E, Mozes E. Neonatal lupus erythematosus in offspring of mothers with experimental systemic lupus erythematosus. *Am J Reprod Immunol* 1992; 28: 264-8. [\[CrossRef\]](#)
6. Hofbeck M, Ulmer H, Beinder E, Sieber E, Singer H. Prenatal findings in patients with prolonged QT interval in the neonatal period. *Heart* 1997; 77: 198-204. [\[CrossRef\]](#)
7. Tanaka M, Ikeda T, Suzuki T, Yakubo K, Fukuiya T. A case of fetal bradycardia and sinusoidal like fetal heart rate pattern associated with maternal hypoglycemia. *Fetal Diagn Ther* 1995; 10: 207-9. [\[CrossRef\]](#)
8. Baruteu AE, Schleich JM. Antenatal presentation of congenital long QT syndrome: A prenatal diagnosis not to be missed. *Pediatr Cardiol* 2008; 29: 1131-2. [\[CrossRef\]](#)
9. Friedman DM, Borg M, Rutkovsky L, Buyon JP. Bening fetal bradycardias diagnosed by echocardiography. *Am J Perinatol* 1995; 12: 87-90. [\[CrossRef\]](#)