



# Bladder Dysfunction in Behçet's Disease

## Behçet Hastalığında Mesane Disfonksiyonu

Murat Dinçer<sup>1</sup>, Ömer Onur Çakır<sup>1</sup>, Onur Fikri<sup>2</sup>, Engin Kandıralı<sup>1</sup>

<sup>1</sup>Clinic of Urology, University of Health Sciences Bağcılar Training and Research Hospital, İstanbul, Turkey

<sup>2</sup>Clinic of Urology, Edirne Sultan 1.Murat State Hospital, Edirne, Turkey

*Cite this article as: Dinçer M, Çakır ÖM, Fikri O, Kandıralı E. Bladder Dysfunction in Behçet's Disease. JAREM 2017; 7: 86-8.*

### ABSTRACT

Behçet's disease (BD) is a systemic vasculitis usually seen in young adults, which affects both venous and arterial vessels of the vascular system. Its etiology is still unknown. The pathognomic symptoms are recurrent oral aphthae accompanied with at least two of these; positive pathergy test, skin lesions, recurrent genital ulcers and lesions in the eye. Urogenital involvement usually consists of genital ulcers, urethritis, epididymitis and recurrent cystitis. Bladder involvement is extremely rare and only several cases have been reported. The findings suggest that neurogenic bladder due to neuro-Behçet disease is characterized uro-dynamically by overactive detrusor in storage phase and detrusor sphincter dyssynergia in voiding phase. We aimed to present several aspects of bladder involvement of Behçet disease in this case report.

**Keywords:** Behçet, neurogenic bladder, overactive detrusor, anticholinergic

### ÖZ

Behçet Hastalığı, vasküler sistemin hem arteriyel hem de venöz damarlarını tutan, genellikle genç erişkinlerde görülen sistemik bir vaskülitir. Etiyolojisi halen bilinmemektedir. Patognomik belirtileri; rekürren oral aft ile birlikte pozitif paterji testi, deri lezyonları, rekürren genital ülserler ve göz lezyonlarından en az ikisinin varlığıdır. Ürogenital tutulum genellikle genital ülserler, üretrit, epididimit ve rekürren sistiti içerir. Mesane tutulumu oldukça nadirdir ve sadece birkaç vaka rapor edilmiştir. Ürodinamik olarak nöro Behçet hastalığında gelişen nörojenik mesane bulguları; depolama fazında aşırı aktif mesane ve boşaltım fazında detrusor sfinkter dissinerjisi. Biz bu vaka sunumunda mesane tutulumunun bazı açılarını sunmayı amaçladık.

**Anahtar Sözcükler:** Behçet, nörojen mesane, aşırı aktif detrusor, antikolinergik

### INTRODUCTION

Behçet's disease (BD) is a systemic vasculitis usually seen in young adults, which affects both venous and arterial vessels of the vascular system (1). Its etiology is still unknown (1). The pathognomic symptoms are recurrent oral aphthae accompanied with at least two of these; positive pathergy test, skin lesions, recurrent genital ulcers and lesions in the eye (2).

Urogenital involvement usually consists of genital ulcers, urethritis, epididymitis and recurrent cystitis. Bladder involvement is extremely rare and only several cases have been reported (3). The findings suggest that neurogenic bladder due to neuro-Behçet disease is characterized urodynamically by overactive detrusor in storage phase and detrusor sphincter dyssynergia in voiding phase (4). We aimed to present several aspects of bladder involvement of Behçet disease in this case report.

### CASE PRESENTATION

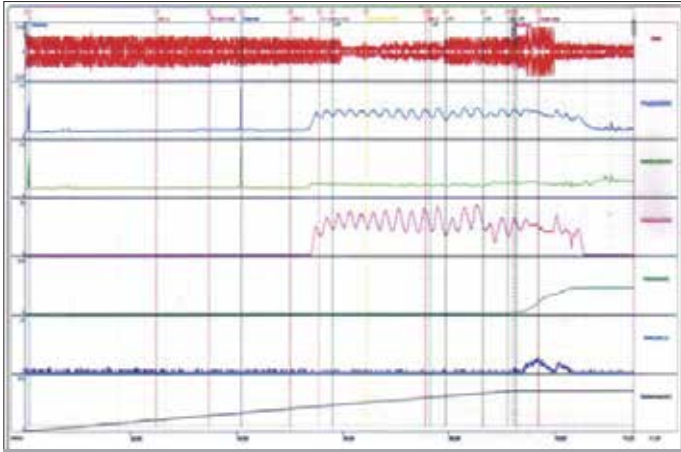
Informed consent document was written and signed by the patient. A 27 year-old man admitted to our institution with chief complaint of urinary incontinence and erectile dysfunction in September 2014. He had a history of Behçet's disease since April 2013. The patient was under systemic cyclophosphamide 200mg/day, azathioprine 100mg/day and prednisolone 10mg/day thera-

py since the date of initial diagnosis. During this period patient had severe urge incontinence symptoms. Solifenasine succinate 5 mg/day tablet was started as anticholinergic therapy and symptoms partially recovered. On July 2014, patient was catheterized because of urinary retention then catheter was taken after 24 hours and the patient had spontaneous micturation. Bladder capacity of 365cc and residual volume of 140 cc was reported by which urodynamic tests showed detrusor hyperreflexia (Figure 1). Patient was managed by clear intermittent catheterization (CIC) 6 times/day combined with oral solifenasin 5 mg/day regimen.

### DISCUSSION

Bladder involvement in BD is usually seen in young patients (3, 5). Although the most common symptoms are storage symptoms, urge incontinence may be seen as well (5, 6). Our, 27 year old male, patient's chief complaint was urge urinary incontinence. Additionally, acute urinary retention and voiding symptoms may also be seen (7). Acute urinary retention after anticholinergic therapy was also seen in our case. According to Nakagawa et al. (4) report of three cases; two of them had a complaint of urinary frequency and urinary incontinence while one of them had a complaint of urinary retention. There can be any abnormality in sphincter function although sphincter deficiency or detrusor sphincter dyssynergia have been reported (5, 8). Meatal





**Figure 1.** Urodynamic test determines Detrusor Hyperreflexia

ulceration, sterile urethritis or cystitis can be the main reasons of dysuria (9). Gross hematuria is considered as a very rare symptom (10). Bladder cancer has been reported concomitant with BD as well. It can be sporadically or as a result of cyclophosphamide treatment. Our patient was under systemic cyclophosphamide treatment; but there was no evidence of a bladder malignancy yet. Urethrovaginal and vesicovaginal fistulas can also be seen rarely with BD (10). Increased intravesical pressure may cause hydronephrosis or severe trabeculation of the bladder wall (3). Urodynamic tests may report detrusor hyperreflexia either sporadically or combined with impaired contractility, decreased bladder compliance or capacity, bladder hypersensitivity, hypo- or acontractile bladder and increased postvoid residual urine concomitant to the detrusor hyperreflexia (3, 5- 8, 10). In our case bladder capacity of 365cc and residual volume of 140 cc was reported by which urodynamic tests showed detrusor hyperreflexia.

Neurologic symptoms called as "Neuro-Behçet's Disease" has been reported in 5% to 10% of BD patients, and 5% of these patients had voiding symptoms (11).

Neurologic involvement usually affects the brain stem and can resemble multiple sclerosis, infection of central nervous system and stroke (5-7). Vasculitis inside the pontine micturition center can be the reason of high prevalence of urgency and frequency in BD patients (6). However ulceration or recurrent cystitis of the bladder may be seen as well.

Storage symptoms could be the result of direct involvement of bladder wall, neuro-Behçet's disease or combination of these two mechanisms (1).

A case whose bladder's pathology changed from areflexia to instability with impaired contractility was reported in a study by Porru and colleagues (7). Çetinel et al. (3) reported the incidence of bladder involvement in Behçet's Disease as 0.07% (n=8). The major findings were bladder wall trabeculation (5/8 cases) and bladder ulcer or hypervascularity in cystoscopy (2/8 cases), detrusor hyperactivity (7/8 cases) and low compliance of bladder (4/8 cases) according to that study (3). These findings suggest the main characteristics of neurogenic bladder due to Behçet's disease are detrusor hyperreflexia in the storage phase and detrusor-sphincter dyssynergia in the voiding phase. Voiding dysfunction

can be treated by clean intermittent catheterization where the storage symptoms have been usually managed by anticholinergic agents. As final treatment, our patient was under anticholinergic therapy combined with clear intermittent catheterization (CIC) 6 times/day. Besides this Saito and Miyagawa (12) also suggest that intravesical oxybutynin therapy combined with clear intermittent catheterization has a highly successful rate of detrusor hyperreflexia with fewer side effects, i.e., dry mouth, flushing and obstipation, than oral medication. Recently, intravesical botulinum toxin injection therapy is being used to manage detrusor hyperreflexia. Denys et al. (13) suggest that botulinum toxin injected into the detrusor muscle seems to be an efficient treatment of bladder hyperreflexia for 6 months in patients resistant to anticholinergic drugs. According to Neugart et al. (14) report of 16 cases with refractory detrusor hyperactivity treated with intravesical botulinum-A-toxin injections; the urodynamic parameters of the bladder were improved clearly in all patients, subjective satisfaction was reached in 72.7% with no severe side effects. In addition, augmentation cystoplasty can be a final solution if needed in very rare situations. For example Theodorou et al. (15) reported their case which they had performed clam-type augmentation cystoplasty using sigmoid colon to avoid lower urinary tract symptoms and incontinence. After four years postoperatively; the patient was reported to be dry, and asymptomatic with the combination of clear intermittent catheterization.

## CONCLUSION

Voiding dysfunction in BD patients may be the reason of bladder involvement. Urodynamic tests should be considered in these patients in order to classify the type of voiding dysfunction.

**Informed Consent:** Written informed consent was obtained from patient who participated in this case.

**Peer-review:** Externally peer-reviewed.

**Author Contributions:** Concept – M.D.; Design – M.D.; Supervision – M.D., Ö.O.Ç., O.F.; Resources – M.D., Ö.O.Ç., E.K.; Materials – M.D., Ö.O.Ç., E.K.; Data Collection and/or Processing – M.D., Ö.O.Ç., E.K.; Analysis and/or Interpretation – M.D., E.K.; Literature Search – M.D., Ö.O.Ç., O.F.; Writing Manuscript – M.D., Ö.O.Ç., E.K.; Critical Review – M.D., O.F.; Other – M.D., O.F.

**Conflict of Interest:** No conflict of interest was declared by the authors.

**Financial Disclosure:** The authors declared that this study has received no financial support.

**Hasta Onamı:** Yazılı hasta onamı bu çalışmaya katılan hastadan alınmıştır.

**Hakem Değerlendirmesi:** Dış bağımsız.

**Yazar Katkıları:** Fikir – M.D.; Tasarım – M.D.; Denetleme – M.D., Ö.O.Ç., O.F.; Kaynaklar – M.D., Ö.O.Ç., E.K.; Malzemeler – M.D., Ö.O.Ç., E.K.; Veri Toplanması ve/veya İşlemesi – M.D., Ö.O.Ç., E.K.; Analiz ve/veya Yorum – M.D., E.K.; Literatür Taraması – M.D., Ö.O.Ç., O.F.; Yazıyı Yazan – M.D., Ö.O.Ç., E.K.; Eleştirel İnceleme – M.D., O.F.; Diğer – M.D., O.F.

**Çıkar Çatışması:** Yazarlar çıkar çatışması bildirmemişlerdir.

**Finansal Destek:** Yazarlar bu çalışma için finansal destek almadıklarını beyan etmişlerdir.

## REFERENCES

1. Alizadeh F, Khorrami MH, Izadpanahi MH, Nouri-Mahdavi K, Sichani MM. Bladder Involvement in Behçet's Disease. *Urology Journal* 2012; 9: 347-50.
2. Yurdakul S, Hamuryudan V, Yazici H. Behçet syndrome. *Curr Opin Rheumatol* 2004; 16: 38-42. [\[CrossRef\]](#)
3. Cetinel B, Akpinar H, Tufek I, Uygun N, Solok V, Yazici H. Bladder involvement in Behçet's syndrome. *J Urol* 1999; 161: 52-6. [\[CrossRef\]](#)
4. Nakagawa H, Namima T, Aizawa M, Uchi K, Orikasa S. Three cases of neurogenic bladder due to Neuro-Behçet disease. *Nihon Hinyokika Gakkai Zasshi* 1994; 85: 1399-402. [\[CrossRef\]](#)
5. Erdogru T, Kocak T, Serdaroglu P, Kadioglu A, Tellaloglu S. Evaluation and therapeutic approaches of voiding and erectile dysfunction in neurological Behçet's syndrome. *J Urol* 1999; 162: 147-53. [\[CrossRef\]](#)
6. Karandreas N, Tsivgoulis G, Zambelis T, Kokotis P, Rapidi A, Petropoulou K, et al. Urinary frequency in a case of Neuro-Behçet disease involving the brainstem - clinical, electrophysiological and urodynamic features. *Clin Neurol Neurosurg* 2007; 109: 806-10. [\[CrossRef\]](#)
7. Porru D, Pau AC, Scarpa RM, Scarpa RM, Zanolla L, Cao A, et al. Behçet's disease and the neuropathic bladder: urodynamic features: case report and a literature review. *Spinal Cord* 1996; 34: 305-7. [\[CrossRef\]](#)
8. Sakakibara R, Hattori T, Boku K, Uchiyama T, Yamanishi T. Micturitional disturbance in neuro-Behçet's syndrome. *Auton Neurosci* 2000; 83: 86-9. [\[CrossRef\]](#)
9. Kirkali Z, Yigitbasi O, Sasmaz R. Urological aspects of Behçet's disease. *Br J Urol* 1991; 67: 638-9. [\[CrossRef\]](#)
10. Cetinel B, Obek C, Solok V, Yaycioglu O, Yazici H. Urologic screening for men with Behçet's syndrome. *Urology* 1998; 52: 863-5. [\[CrossRef\]](#)
11. Davatchi F, Shahram F, Chams-Davatchi C, Shams H, Nadji A, Akhlaghi M, et al. Behçet's disease: from East to West. *Clin Rheumatol* 2010; 29: 823-33. [\[CrossRef\]](#)
12. Saito M, Miyagawa I. Bladder dysfunction due to Behçet's Disease. *Urol Int* 2000; 65: 40-2. [\[CrossRef\]](#)
13. Denys P, Even-Schneider A, Thiry Escudie I, Ben Smail D, Ayoub N, Chartier-Castler E. Efficacy of botulinum toxin A for the treatment of detrusor hyperreflexia. *Ann Readapt Med Phys* 2003; 46: 326-8. [\[CrossRef\]](#)
14. Neugart F, Groh R, Götz T, Horsch R. Injections of botulinum toxin A into the detrusor vesicae for treatment of refractory detrusor hyperactivity in non-neurological patients. *Aktuelle Urol* 2006; 37: 212-7. [\[CrossRef\]](#)
15. Theodorou C, Floratos D, Hatzinicolaou P, Vaiopoulos G. Neurogenic bladder dysfunction due to Behçet's disease. *Int J Urol* 1999; 6: 423-5. [\[CrossRef\]](#)