









Comparison of Pilonidal Sinus Repair Techniques: Phenol Application After Minimal Surgical Excision and Flap Repair

Pilonidal Sinüs Tedavisinde Minimal Cerrahi Eksizyon Sonrası Kristalize Fenol Uygulamasının Flep Tamiri ile Karşılaştırılması

Doğan Gönüllü¹ , Mehmet Lari Gedik² , A. Serkan Ilgun¹ , A. Muzaffer Er¹ , Zeki Öner¹ , Metin Keskin³ , Ferda Nihat Koksoy¹ 

¹Clinic of General Surgery, Health Sciences University Gaziosmanpaşa Taksim Training and Research Hospital, İstanbul, Turkey

²Clinic of General Surgery, Fatsa State Hospital, Fatsa, Turkey

³Department of General Surgery, İstanbul University School of Medicine, İstanbul, Turkey

Cite this article as: Gönüllü D, Gedik ML, Ilgun AS, Er AM, Öner Z, Keskin M, et al. Comparison of Pilonidal Sinus Repair Techniques: Phenol Application After Minimal Surgical Excision and Flap Repair. JAREM 2018; 8(3): 133-7.

ABSTRACT

Objective: To compare the results of pilonidal sinus repair techniques using crystallized phenol after a minimal excision and flap repair.

Methods: Patients who underwent surgery between 2008 and 2014 at Health Sciences University Gaziosmanpaşa Taksim Training and Research Hospital were enrolled in the study. Patients who underwent flap repairs with complete excision (group A; n=100) were compared with patients who were treated with minimal excision and crystallized phenol (group B; n=100) in terms of demographic data, postoperative early complication, duration of hospitalization, wound healing time, return-to-work times, recurrence rates, and late complications.

Results: In group A, 45 (45%) patients had a history of abscess, and 16 (16%) patients had recurrence. In group B, 35 (35%) patients had a history of abscess, and 18 (18%) patients had recurrence. The mean time periods between the first symptom and presentation to the clinic were 6 and 7 months, respectively, and the median follow-up durations were 44 and 34 months, respectively. The mean duration of hospitalization was significantly shorter in group B (1.1 days) than in group A (3.7 days) ($p<0.0001$). The duration of postoperative wound healing was significantly shorter in group B (10.1 days) than in group A (18.9 days) ($p<0.0001$). The return-to-work time was significantly shorter in group B (6.4 days) than in group A (19.2 days) ($p<0.0001$).

Conclusions: Crystallized phenol application following minimal surgical excision was found to be better than complete excision in flap procedures in terms of duration of wound healing, hospitalization, and return-to-work and late complications (numbness, poor esthetics).

Keywords: Crystallized phenol in pilonidal sinus, flap repair, pilonidal sinus

ÖZ

Amaç: Pilonidal sinüs tedavisinde, minimal cerrahi eksizyon sonrası uygulanan kristalize fenol ile geniş eksizyon sonrası uygulanan flep tamirleri ile sonuçlarının karşılaştırılması.

Yöntemler: Sağlık Bilimleri Üniversitesi Gaziosmanpaşa Taksim Eğitim ve Araştırma Hastanesi, genel cerrahi kliniğinde 2008-2014 yılları arasında ameliyat edilmiş olan hastaların kayıtları gözden geçirildi; pilonidal sinüs tedavi amacı ile geniş eksizyon sonrası oluşan defekt flep ile kapatılmış (grup A, n:100), minimal eksizyon sonrası kristalize fenol uygulanmış (grup B, n:100) demografik bilgiler, yatış süresi, erken ve geç komplikasyonlar, yara iyileşme süresi, işe başlama süresi ve nüks yönünden karşılaştırıldı.

Bulgular: Grup A'da 45 hasta (%45) apse öyküsü tarif etmiş, 16 hasta (%16) nüks vakadır. Grup B'de 35 hasta (%35) apse geçmişi tarif etmektedir, bu grupta 18 hasta (%18) nüks olarak kaydedilmişler. Semptomların başlangıcı ile hastaların başvuru arasında geçen süre ortalama olarak 6 ay ve 7 aydır, ortalama takip süreleri 44 ve 34 aydır. Hastane yatış süreleri, grup B grubunda (1,1 gün), grup A grubuna (3,7 gün) göre daha kısadır ($p<0,0001$). Ameliyat sonrası yara iyileşme süresi, B grubundaki hastaların (10, 1 gün) A grubundaki hastalarına (18, 9 gün) göre anlamlı olarak daha kısa bulunmuştur ($p<0,0001$). İşe başlama süresi B grubunda (6, 4 gün) A grubuna (19, 2 gün) göre anlamlı bir şekilde daha kısa bulunmuştur ($p<0,0001$).

Sonuç: Minimal eksizyon sonrası fenol uygulama, eksizyon sonrası flep prosedürlerinin sonuçlarına göre yara iyileşme süreleri, hastanede yatış ve işe dönme süreleri, erken ve geç komplikasyonlar (hissizlik, kötü estetik) açısından daha avantajlı olduğu saptanmıştır.

Anahtar kelimeler: Pilonidal sinüs ve kristalize fenol uygulaması, flep tamiri, pilonidal sinüs

ORCID IDs of the authors: D.G. 0000-0002-8232-520; M.L.G. 0000-0002-0440-9394; A.S.I. 0000-0002-4862-2891; A.M.E 0000-0001-8578-1229; Z.Ö. 0000-0003-2729-2202; M.K. 0000-0002-5390-2185; F.N.K. 0000-0002-5878-7489.

This study was presented in European Society of Coloproctology, Tenth Scientific and Annual General Meeting, 23-25 September 2015, Dublin, Ireland.

INTRODUCTION

Even though modern surgery has achieved consensus on the treatment of many major diseases, treatment of the pilonidal sinus is still open to discussion. Hygiene and removal of regional hair have been commonly accepted as a prerequisite for all treatment options (1-3).

A pilonidal sinus is a small cyst or abscess that occurs in the cleft at the top of the buttocks. There are many surgical and non-surgical methods for treating pilonidal sinus. To date, no treatment method has been able to absolutely prevent recurrence because there is a lack of consensus on its origins and treatment. The most widely accepted theory suggests that the disease results from infected hair follicles in the intergluteal sulcus, which occur especially after microtraumas (4, 5). Treatment has to target the etiology in order to achieve positive results (1, 6).

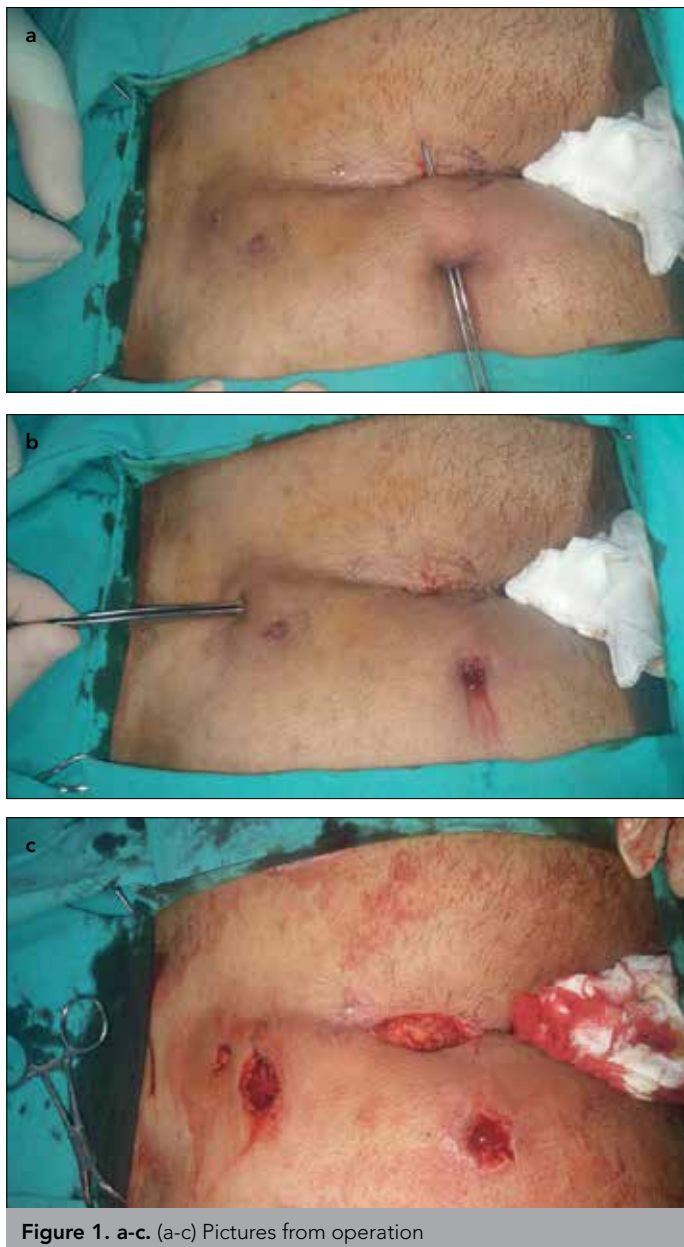

Figure 1. a-c. (a-c) Pictures from operation

Excision and primary closure, marsupialization, various flap techniques, and crystallized phenol application are the most common treatment methods for pilonidal sinus. An ideal surgical technique should be low cost for both the patient and society; be easy to conduct; have low hospitalization, complication, and recurrence rates; and result in low postoperative pain (1).

In the present study, we retrospectively compared the "large excision and flap reconstruction" technique with the "minimal excision and crystallized phenol" technique, both of which are performed in our clinic in patients with pilonidal sinus.

METHODS

The aim of the present study was to retrospectively compare "complete excision and flap" and "minimal excision and crystallized phenol" in the surgical treatment of pilonidal sinus in the University of Health Sciences Gaziosmanpaşa Taksim Training and Research Hospital, General Surgery Department between 2008 and 2014. All patients were informed about the possible complications in detail. Written consent was obtained from the patients. Both techniques were compared on the basis of duration of hospitalization, wound healing time, early and late complications, return-to-work time, and recurrence. The study was designed in conformity with the Declaration of Helsinki. There was no need for ethical approval because this is a retrospective study.

Group A (flap; n=100) consisted of patients who underwent flap operation following complete excision (Limberg flap), and group B (phenol; n=100) comprised patients who had crystallized phenol application after a minimal excision. The procedure was performed after local anesthesia or regional anesthesia; the minimal excision procedure (group B) included excision or curettage of the primary sinus opening, subcutaneous collection sites, and epithelialized tracts leading to the secondary pits with minimal tissue loss; the adjacent area was coated with nitrofurantoin ointment, and phenol crystals (Botapharma Laboratories, Ankara, Turkey) were applied with a clamp to the recently formed cavity (Figure 1a, b, c). The wound was closed with a gauze pack. Some of the procedures were conducted daily; patients were informed that they could take a bath on the next day and should not limit themselves in terms of their physical activities. Patients were asked to visit the hospital for postoperative follow-up controls weekly within month 1 and at months 6 and 12 thereafter. At the controls when no more leakage from the wound was observed, the treatment was terminated; if leakage from the wound was observed, the procedure described above was repeated.

Recurrence was defined as reappearance of the sinus and leakage after healing had been reached. Patients were contacted by phone before the article was written.

Statistical Analysis

Data analyzes were performed using the Statistical Package for the Social Sciences version 22.0 (IBM SPSS Corp.; Armonk, NY, USA). The Kolmogorov-Smirnov test was used for the distribution of variables. Quantitative data were analyzed using the independent samples t-test and Mann-Whitney U test. Qualitative data were analyzed using the chi-square test.

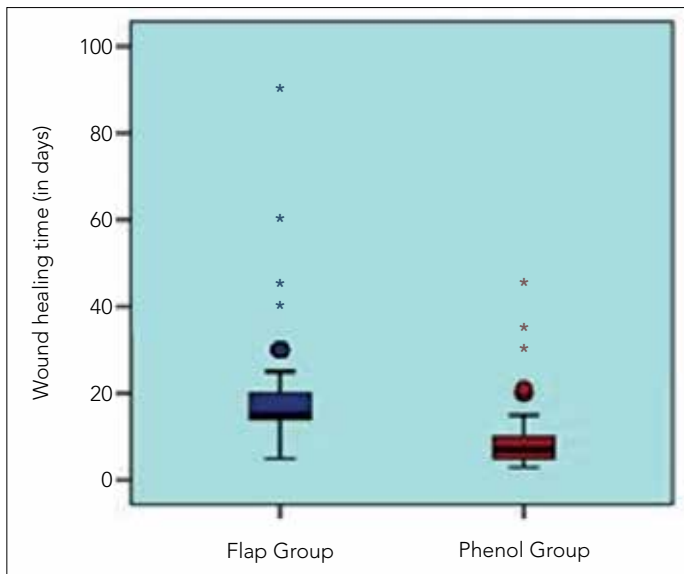


Figure 2. Duration of wound healing

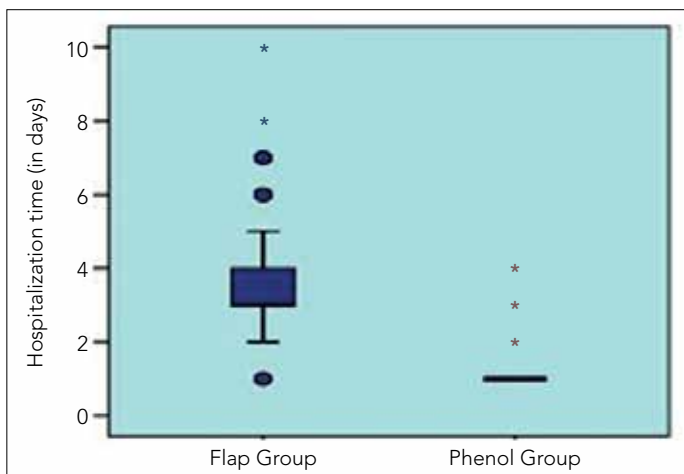


Figure 3. Duration of hospitalization

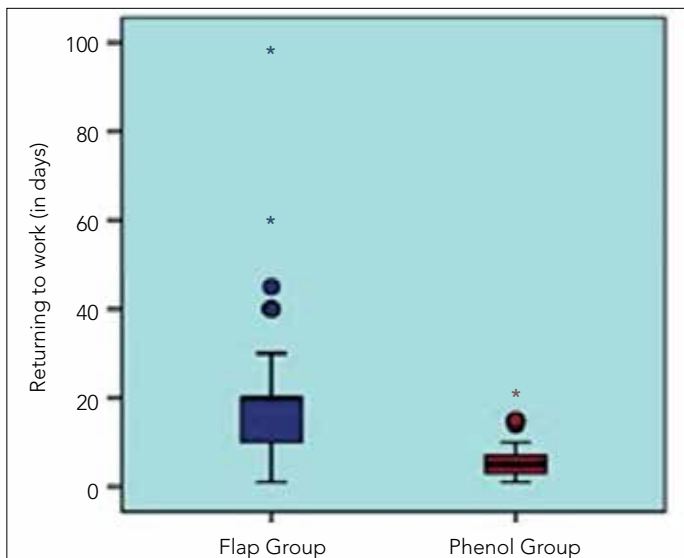


Figure 4. Time required for returning to work

RESULTS

The mean ages were 23 (range: 16-47) years for group A (87 males and 13 females) and 24.9 (range: 15-51) years for group B (82 males and 18 females). The two groups did not differ in terms of age ($p=0.313$) and sex ($p=0.329$).

Of the 45 (45%) patients in group A, 16 had a history of previous surgery, and the mean duration between the first symptom and presentation to the clinic was 6 (range: 2 weeks-3 years) months. The mean follow-up for this group was 44 (range: 29-61) months.

In patients in group B, 35 (35%) had a history of abscess, and 18 (18%) had a history of recurrence. The mean duration between the first symptom and presentation to the clinic was 7 (range: 2 weeks-8 years) months. The mean follow-up duration for this group was 34 (range: 21-48) months. The median number of phenol application was 1 (1-3), and the application was once in the majority of patients.

Wound healing times were 18.9 ± 11.9 days in group A and 10.1 ± 7.8 days in group B. The difference between the groups indicated significantly favorable results for group B ($p < 0.0001$) (Figure 2).

The mean hospitalization time was 3.7 ± 1.5 days for group A, whereas it was 1.1 ± 0.4 days for group B. The difference between the groups was statistically significant in favor of group B ($p < 0.0001$) (Figure 3).

The average times required for returning to work were 19.2 ± 12.6 days in group A and 6.4 ± 4.2 days in group B. The difference was statistically significant ($p < 0.0001$) (Figure 4).

In terms of early complications, wound dehiscence and seroma were observed in eight patients in group A, and no seroma in group B ($p=0.007$). Two patients in group A and four patients in group B had wound infections.

In terms of late complications, numbness, and bad cosmetic results were observed only in seven (7%) patients in group A, and the difference was statistically significant ($p=0.014$) in favor of group B.

Follow-up revealed five cases of recurrence in group A and three cases in group B. There was no statistically significant difference between the groups ($p=0.721$).

DISCUSSION

Even though various conservative and surgical methods have been defined for the treatment of pilonidal sinus, none of them have eliminated the risk of recurrence (6-8).

For a long time, excision without closure was used. Thereafter, post-excision defects started to be closed with large and time-consuming flaps; this technique is still being used. More recently, the idea of controlling the disease, rather than eliminating it completely, has gained popularity. According to this view, fast-healing minimally invasive methods that can prevent cosmetic problems caused by large flaps in the gluteal area and cause less tissue loss should be chosen (8, 9).

Most minimalist methods in pilonidal sinus treatment require clearing hair and debris that has accumulated in the sinus and

periodically shaving the region (2, 3, 8, 10). In addition, studies using 80% phenol solution or phenol crystal to destroy the sinus wall epithelia have reported 60%-95% success rates (11-15).

In a large series with 1358 patients, recurrence rates solely for curettage/excision of the sinus epithelia with trephines were reported as 6.5% for year 1, 13.2% for year 5, and 16.2% for year 10. The mean recurrence time was 2.7 years (16).

Phenol is an aromatic hydrocarbon with acidic properties. It can be used as liquid or in crystallized forms. The crystallized form is easier to handle than the liquid form; the latter has the disadvantage to cause skin and tissue necrosis in the surrounding area (17). Phenol application is preferred because it has a low cost and requires only local anesthesia with short hospitalization times. In the conventional technique, entrance and exit pits are expanded, hairballs in the cavities are cleaned off, and liquid or crystal phenol is injected into the cavities. The success rates of the conventional technique vary significantly. Kayaalp et al. (13) used liquid phenol as a single application and reported 70% success after 14 months of follow-up. The authors reported the average healing duration as 25 (range: 10-63) days. Dogru et al. (18) used crystal phenol in repeated applications (2-3 times for 70% of the patients) and reported 95.1% success after a 24-month follow-up period, and they suggested this modality of treatment as the first-line treatment. In our study, the median number of phenol application was 1 (1-3), and the application was once in the majority of patients. The follow-up duration was 34 (range: 21-48) months, and the wound healing time, length of hospitalization, recurrence, and complication rates were found to be lower in the phenol applied group than in patients who underwent wide excision and flap reconstruction. The advantage of minimal excision with crystallized phenol application is its repeatability in patients with recurrence without modification of presacral zone appearance.

Akan et al. (19) curated the epithelia, injected crystallized phenol into the sinus after cleaning the hair off, and compared this method with the Limberg flap technique. At 26 months of follow-up, recurrence rates were 8% for the flap group and 12% for the phenol group. However, this difference was not statistically significant. The authors reported that the phenol group had superior cosmetic appearance.

A combination of minimally invasive surgery and phenol procedure was performed by Kasım et al. (20) The authors injected 81% liquid phenol into the cavity following minimal excision and cleaned the accumulation in the cavity within 5 min. Some 60.6% of the patients had three sessions, and 39.4% underwent four sessions. The study reported 5.2% recurrence after 12 months of follow-up (20).

In our study, pilonidal pits were excised with minimal tissue loss (when multiple pits were present, all were included within a single excision). Recently, Meineri et al. (21) applied the same principle using videoendoscopy (21). One study used Meineri's endoscopic pilonidal sinus treatment technique in 33 patients. They followed up 27 out of 33 patients. Forty-one percent of the patients had multiple pits 2.4±0.9 cm to the midline. The authors reported 93% patient satisfaction, 96% good cosmetic results, and 1 recurrence (in month 2) for postoperative year 1 (22).

We used crystallized phenol for sinus destruction instead of liquid phenol in order to protect the surrounding healthy tissue. Compared with complete excision and flap technique, patients who received minimal excision and crystallized phenol had significantly less seroma and wound healing complications, shorter hospitalization, returned to work more quickly, and their wounds healed faster. Even though it was not statistically significant, recurrence numbers were also lower.

An unpleasant scar was observed after the flap procedure, whereas the scar after minimal excision and phenol application is unremarkable. An unsuccessful use of phenol application in multiple sinus orifices has been previously reported (5). In our study, many (Figure 1a, b, c) patients had multiple sinus openings, and this situation did not change the rate of recurrence.

Recurrence and unhealed advanced wounds are difficult to treat and are traditional candidates for treatment with complete excision and flap techniques. On the other hand, approximately 70% cure rates have been reported with conservative methods (9). Aygen et al. (23) used crystallized phenol in 36 patients with recurrence who had previously been treated with primary repair and flap procedures and reported 13.9% recurrence rate in postoperative month 54. In our study, the same procedure was performed in 18 cases of recurrence, and successful results were obtained.

CONCLUSION

Applying crystallized phenol following minimal excision is easy, may be performed as outpatient, or with minimal hospitalization time in primary or recurrent pilonidal sinus disease; therefore, we recommend it as a first option in pilonidal sinus treatment.

Ethics Committee Approval: Authors declared that the research was conducted according to the principles of the World Medical Association Declaration of Helsinki "Ethical Principles for Medical Research Involving Human Subjects", (amended in October 2013).

Informed Consent: Written informed consent was obtained from patients who participated in this study.

Peer-review: Externally peer-reviewed.

Author Contributions: Concept - D.G., M.L.G., F.N.K.; Design - D.G., M.L.G., F.N.K.; Supervision - D.G., M.L.G., Z.Ö., A.M.E.; Resources - A.M.E., M.K., A.S.I., Z.Ö.; Data Collection and/or Processing - D.G., M.K., A.S.I., Z.Ö.; Analysis and/or Interpretation - F.N.K., D.G., M.L.G., A.M.E.; Literature Search - Z.Ö., A.S.I., M.K.; Writing Manuscript - D.G., M.L.G., F.N.K.; Critical Review - D.G., F.N.K., M.K., A.S.I.

Conflict of Interest: The authors have no conflict of interest to declare.

Financial Disclosure: The authors declared that this study has received no financial support.

Etik Komite Onayı: Yazarlar çalışmanın World Medical Association Declaration of Helsinki "Ethical Principles for Medical Research Involving Human Subjects", (amended in October 2013) prensiplerine uygun olarak yapıldığını beyan etmişlerdir.

Hasta Onamı: Bu çalışmaya katılan kişilerden yazılı onam alınmıştır.

Hakem Değerlendirmesi: Dış bağımsız.

Yazar Katkıları: Fikir - D.G., M.L.G., F.N.K.; Tasarım - D.G., M.L.G., F.N.K.; Denetleme - D.G., M.L.G., Z.Ö., A.M.E.; Kaynaklar - A.M.E., M.K., A.S.I.,

Z.Ö.; Veri Toplanması ve/veya İşlemesi - D.G., M.K., A.S.I., Z.Ö.; Analiz ve/veya Yorum - F.N.K., D.G., M.L.G., A.M.E.; Literatür Taraması - Z.Ö., A.S.I., M.K.; Yazıyı Yazan - D.G., M.L.G., F.N.K.; Eleştirel İnceleme - D.G., F.N.K., M.K., A.S.I.

Çıkar Çatışması: Yazarların beyan edecek çıkar çatışması yoktur.

Finansal Destek: Yazarlar bu çalışma için finansal destek almadıklarını beyan etmiştir.

REFERENCES

- Kooristra HP. Pilonidal sinuses, Review of literature and report of three hundred and fifty cases. *Am J Surg* 1942; 55: 3-17.
- Conroy FJ, Kandamany N, Mahaffey PJ. Laser depilation and hygiene: preventing recurrent pilonidal sinus disease. *J Plast Reconstr Aesthet Surg* 2008; 61: 1069-72. [CrossRef]
- Bolandparvaz S, Moghadam Dizaj P, Salahi R, Paydar S, Banazadeh M, Abbasi HR, et al. Evaluation of the risk factors of pilonidal sinus: A single center experience. *Turk J Gastroenterol* 2012; 23: 535-7. [CrossRef]
- Cemalettin C. Pilonidal Sinus Disease: Definition, Epidemiology, Pathophysiology, Clinical Outcome. *Türkiye Klinikleri J Gen Surg-Special Topics* 2018; 11: 85-7.
- John J, Franckowiak, Raymond J. The etiology of pilonidal sinus. *Dis Colon and Rectum* 1962; 5: 2836.
- Sondenaa K, Andersen E, Soreide JA. Morbidity and short term results in a randomised trial of open compared with closed treatment of chronic pilonidal sinus. *Eur J Surg* 1992; 158: 351-5.
- Gencosmanoglu R, Inceoglu R. Modified lay-open (incision, curettage, partial lateral wall excision and marsupialization) versus total excision with primary closure in the treatment of chronic sacrococcygeal pilonidal sinus. *Int J Colorect Dis* 2005; 20: 415-22. [CrossRef]
- Stauffer VK, Luedi MM, Kauf P, Schmid M, Diekmann M, Wieferrich K, et al. Common surgical procedures in pilonidal sinus disease: a meta-analysis, merged data analysis, and comprehensive study on recurrence. *Sci Rep* 2018; 8: 3058. [CrossRef]
- Kronborg O, Christensen K, Zimnermann-Nielsen C. Chronic pilonidal disease: a randomized trial with a complete 3 year follow-up. *Br J Surg* 1985; 72: 303-4. [CrossRef]
- Steele SR, Perry WB, Mills S, Buie WD; Standards Practice Task Force of the American Society of Colon and Rectal Surgeons. Practice parameters for management of pilonidal disease. *Dis Col Rectum* 2013; 56: 1021-7. [CrossRef]
- Hegge HG, Vos GA, Patka P, Hoitsma HF. Treatment of complicated or infected pilonidal sinus disease by local application of phenol. *Surgery* 1987; 102: 52-4.
- Humphries AE, Duncan JE. Evaluation and management of pilonidal disease. *Surg Clin North Am* 2010; 90: 113-24. [CrossRef]
- Kayaalp C, Olmez A, Aydın C, Piskin T, Kahraman L. Investigation of one-time phenol application for pilonidal disease. *Med Princ Pract* 2010; 19: 212-5. [CrossRef]
- Bayhan Z, Zeren S, Düzgün SA, Ucar BI, Alparslan Yumun HN, Mes-tan M. Crystallized phenol application and modified Limberg flap procedure in treatment of pilonidal sinus disease: A comparative retrospective study. *Asian J Surg* 2016; 39: 172-7. [CrossRef]
- Topuz O, Sözen S, Tükenmez M, Topuz S, Vurdem UE. Crystallized phenol treatment of pilonidal disease improves quality of life. *Indian J Surg* 2014; 76: 81-4. [CrossRef]
- Gips M1, Melki Y, Salem L, Weil R, Sulkes J. Minimal surgery for pilonidal disease using trephines: description of a new technique and long-term outcomes in 1.358 patients 2008; 51: 1656-63.
- Sakçak I, Avsar FM, Cosgun E. Comparison of the application of low concentration and 80% phenol solution in pilonidal sinus disease. *JRSM Short Rep* 2010; 1: 5. [CrossRef]
- Dogru O, Camcı C, Aygen E, Girgin M, Topuz O. Pilonidal sinus treated with crystalized phenol: An eight-year experience. *Dis Colon Rectum* 2004; 47: 1934-8. [CrossRef]
- Akan K, Ihan D, Duman U, Özgün Y, Erol F, Polat M. Pilonidal sinus tedavisinde cerrahi Limberg flep yöntemi ile kristalize fenol uygulamasının retrospektif karşılaştırılması. *Turk J Surg* 2013; 29: 162-6. [CrossRef]
- Kasım M, Arık I, Borazan E. Pilonidal sinuste minimal invaziv cerrahi ile kombine fenol uygulamalarımız *Anatol J Clin Investig.* 2011; 5: 165-8.
- Meinero P, Mori L. Pilonidal sinus treatment (EPSİT). In: Gagliardi G, Lund J, editors. *Techniques in Coloproctology*. Switzerland: Springer; 2014.p.389-92.
- Milone M, Musella M, Di Spiezio Sardo A, Bifulco G, Salvatore G, Sosa Fernandez LM, et al. Video-assisted ablation of pilonidal sinus: A new minimally invasive treatment-A pilot study. *Surgery* 2014; 155: 562-6. [CrossRef]
- Aygen E, Aslan K, Dogru O, Basbug M, Camcı C. Crystallized phenol in non-operative treatment of previously operated, recurrent pilonidal disease. *Dis Col Rectum* 2010; 53: 932-5. [CrossRef]